

ONCOLOGY. Vol. 27 No. 5
CLINICAL QUANDARIES

Rising PSA Level in a 46-Year-Old Man

By E. David Crawford, MD¹ | May 15, 2013

¹University of Colorado Health Sciences Center, Denver, Colorado

The Case:

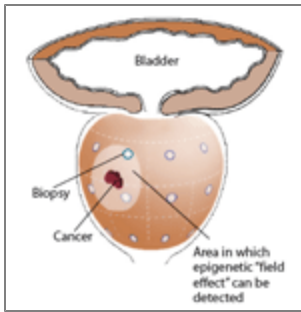
A 46-year-old man sought consultation for an abnormal prostate-specific antigen (PSA) level of 9 ng/mL and one prior negative biopsy. Five months ago, while traveling, he had presented to an urgent care facility with a 24-hour history of fever, chills, nausea, and vomiting. He required intravenous hydration, and a urinalysis suggested a urinary tract infection. Subsequent culture grew > 100,000 Escherichia coli organisms. He was treated with ciprofloxin (Cipro) and had relief of symptoms. On his return home he saw his primary care doctor. A PSA level was obtained and was 13 ng/mL. He was referred to a urologist, who performed a digital rectal exam and felt some asymmetry; to follow up, he ordered a CT scan and scheduled a biopsy. The transrectal ultrasound (TRUS) identified a 34-gram gland with no abnormalities; 12 core biopsies were obtained. The cores showed areas of inflammation but no suspicion of cancer.

One month later, the patient's asymmetry had improved; however, his PSA level was still elevated. An infectious disease consult was obtained to rule out the presence of a granulomatous process such as tuberculosis; the evaluation was negative. The PSA level was 9 ng/mL.

It was recommended that he follow up with the urologist in 6 months. He was a little concerned about his PSA level and sought evaluation at our institution. He appeared healthy; he had some mild urinary obstructive symptoms and normal sexual function. Results of a urinalysis were normal, and on rectal exam, the prostate was normal. A Progenesa prostate cancer antigen 3 (PCA3) test was obtained, and the PCA3 score (ratio of PCA3 RNA to PSA RNA) was 53 (normal, less than 25); his PSA level at this point was 6.1 ng/mL. Because of concerns raised by results of both the PSA and PCA3 tests, the [paraffin \(Drug information on paraffin\)](#) blocks from his 12 core biopsies were obtained for the performance of a molecular marker test called ConfirmMDx. The ConfirmMDx test identified three areas of concern in the right apex and right base of the patient's gland. An endorectal coil MRI also suggested abnormalities in the apex, base, and midprostate. TRUS-directed biopsies were performed and confirmed the presence of Gleason 3+3=6 in the right apex and base. A standard set of 12 core biopsies also detected "xanthogranulomatous inflammation." The patient was relieved to know the diagnosis and was scheduled for a nerve-sparing radical prostatectomy.

Discussion

FIGURE



Identification of Occult Prostate Cancer With New Test Using Three “Field-Effect” Biomarkers

Since 1994, the PSA test has been the workhorse of our efforts to detect prostate cancer early, and has also been the focus of much controversy regarding the value of early detection. Much of the debate stems from difficulties in determining who may benefit from treatment.

Regardless of one’s opinion on mass screening, most would agree that detection and treatment in a healthy 46-year-old man would be beneficial. This case presents the quandary of a negative biopsy in the framework of an elevated PSA level in a young man. However, molecular tests are now available that can help us determine whether this patient—and others who present with indeterminate clinical evidence—might have the disease, and who among such patients might benefit from further observation. We also have tests available to help guide treatment. We have entered the age of molecular evaluation of the prostate.

We evaluated a large cohort of men and determined that a PSA level of > 1.5 ng/mL increases a man’s risk of prostate cancer.[1] We examined a man’s future risk of prostate cancer based on initial PSA level. Using a database of over 350,000 men and identifying first PSA values, we found that the risk increased by a factor of 12.4 if this first value was just above 1.5 ng/mL. In African American men, the risk increased 17-fold. So clearly this patient is at high risk for cancer.

I have seen men biopsied over a dozen times to follow up steadily rising PSA levels until a cancer was found. In this case, we turned to molecular markers to aid us in establishing the cause of this man’s elevated PSA levels. First, the Progenza PCA3 test was employed to help us determine whether another biopsy was indicated. This urinary test, approved in February 2012, looks for the expression of a messenger RNA called PCA3. The PCA3 gene is overexpressed in prostate cancer, and the messenger RNA can be detected in the urine. In our study of this test in association with PSA levels in 1,900 men, a score of above 25 was determined to be abnormal.[2] Based on this patient’s score of 53, we were able to ascertain that another biopsy was clearly indicated—but how could we be better at targeting where a potential cancer was hiding?

We could have tried to find the location by another set of random TRUS biopsies. However, when we biopsy prostates, we sample less than 1% of the gland. So there is a lot of hit and miss that occurs. Instead, we sought assistance from another molecular marker. We obtained the outside paraffin blocks from the patient’s earlier biopsy and sent them off for a second test called ConfirmMDx. This test, which was released in May 2012, looks at epigenetic changes around known areas of cancer. It could be said that ConfirmMDx roots out false negatives by detecting halo effects that a cancer produces in seemingly normal nearby cells (Figure). Using the results of this patient’s ConfirmMDx testing, directed biopsies found the low-grade cancers.

Other ways to sample the gland include increasing the number of TRUS-directed biopsies, sort of a “drill more holes, find more oil” approach. However, transrectal biopsies are limited, both in the number a patient can tolerate as well as in how much of the gland, particularly the anterior gland, can actually be sampled. The morbidity of the procedure is apparent in the increased rate of serious infections reported as resulting from TRUS biopsies. One way around this limitation is to use transperineal mapping biopsies, which allow for complete and accurate sampling of the gland. However, this procedure requires an anesthetic and is time consuming.[3]

There are now a number of new biomarkers that can aid in the diagnosis of this disease, and we need to better understand their capabilities. In addition, there are markers now available that can assist in determining prognosis, including the OncoDx and Prolaris tests. These look at cell cycle progression—and in the case of OncoDx, at cell cycle progression along with other genes—to predict outcomes. We are in the process of evaluating these assays in clinical practice. While it might have been interesting to perform one of these tests in this man, given his young age (46) and multicentric cancers, the best path forward for him in my opinion was definitive treatment. However, if he had been 60 or older, then these other molecular markers could have helped us decide between treatment and active surveillance.

Financial Disclosure: *Dr. Crawford has received research support from Gen-Probe, and he has served as a consultant to Myriad Genetics.*

References

1. Crawford ED, Moul JW, Rove KO, et al. Prostate-specific antigen 1.5-4.0 ng/mL: a diagnostic challenge and danger zone. *BJU Int.* 2011;108:1743-9.
2. Crawford ED, Rove KO, Trabulsi EJ, et al. Diagnostic performance of PCA3 to detect prostate cancer in men with increased prostate specific antigen: a prospective study of 1,962 cases. *J Urol.* 2012;188:1726-31.
3. Barqawi AB, Rove KO, Gholizadeh S, et al. The role of 3-dimensional mapping biopsy in decision making for treatment of apparent early stage prostate cancer. *J Urol.* 2011;186:80-5.